



Case report

Primary Complex Total Hip Arthroplasty in Neglected Anterior Hip Dislocation With Comminuted Pertrochanteric Femur Fracture

Ashish Singh, MBBS, MS Ortho, MChOrth, SICOT D Ortho, Post Graduate Diploma CAOS^{*},
 Purushotam Kumar, MBBS, Sushil Singh, MBBS, D Ortho, DNB Ortho,
 Rabindra Narain Singh, MBBS, MS Ortho, FRCS, MChOrth,
 Kartheek Telagareddy, MBBS, MS Ortho

Department Of Orthopaedics, Anup Institute Of Orthopaedics And Rehabilitation, Patna, Bihar, India

ARTICLE INFO

Article history:

Received 14 January 2021

Received in revised form

3 June 2021

Accepted 5 June 2021

Available online 10 July 2021

Keywords:

Anterior hip dislocation

Neglected

Fracture

Total hip arthroplasty

ABSTRACT

Neglected anterior hip dislocation combined with comminuted pertrochanteric ipsilateral fracture of the femur is rare, with few reports in the literature. The present report describes the case of a 7-month-old neglected anterior hip dislocation with a pertrochanteric femoral fracture in a 45-year-old male patient. The patient was treated with total hip arthroplasty with proximal femoral reconstruction. The 2-year follow-up showed good clinical and radiological outcomes with a painless and mobile hip joint. The Harris-Hip score improved from 10 (preoperatively) to 89 (postoperatively) after 2 years. The patient was satisfied with the intervention and showed minimal lurch with ambulation with no leg-length discrepancy. However, long-term results from periodic follow-up are warranted.

© 2021 The Authors. Published by Elsevier Inc. on behalf of The American Association of Hip and Knee Surgeons. This is an open access article under the CC BY-NC-ND license (<http://creativecommons.org/licenses/by-nc-nd/4.0/>).

Introduction

Unreduced traumatic hip dislocations are common in developing countries and are often due to road traffic accidents [1]. In such situations, reduction techniques should be applied within 6 hours of injury [2]. However, these injuries often coexist with multiple traumas, which distract attention from the dislocation, and thus, a patient may not seek urgent medical care for this injury and instead resort to alternate therapies. Neglecting such injuries leads to difficulty in reduction and increases the risk of avascular necrosis. Furthermore, as time progresses, reduction by closed means becomes impossible, and if the delay is greater than 3 months, open reduction also ceases to be viable [1,3]. The potential options for these types of cases are total hip arthroplasty (THA) or osteosynthesis [3,4].

Traumatic hip dislocations are classified based on the direction of the dislocation, with posterior dislocations 9 times more common than anterior dislocations [5]. While reports of chronic traumatic anterior hip dislocation are very rare [3], such dislocations

with an associated femoral fracture are seen even less frequently [5]. We present one such rare case involving a neglected anterior hip dislocation with a 7-month-old history that was further complicated by a comminuted pertrochanteric ipsilateral femoral fracture.

Case history

We present the case of a 45-year-old male who presented with pain in the left hip and difficulty walking for 7 months. He had been involved in a road traffic accident 7 months prior—the patient was a pillion rider and was hit by a car—for which he did not receive any treatment. After this incident, the patient was on complete bed rest for 3 months. After 3 months, the patient was walking with the help of a stick but was unable to squat or sit cross-legged and had considerable limitations in his activities of daily living. Upon examination, there was apparent shortening of the left lower limb of 6 cm and true shortening of 4 cm with fixed adduction and external rotation deformity. Radiological evaluation was performed using radiographs and CT scans, which showed an anteroinferior dislocation of the femur with comminuted pertrochanteric fracture (Fig. 1b). The potential surgical options, including complex THA with proximal femoral reconstruction or proximal femoral

^{*} Corresponding author. 2m-106, Bahadurpur Housing Colony, Kankarbagh, Patna 800026, Bihar, India. Tel.: +91-8294240349.

E-mail address: drashishsingh@hotmail.com

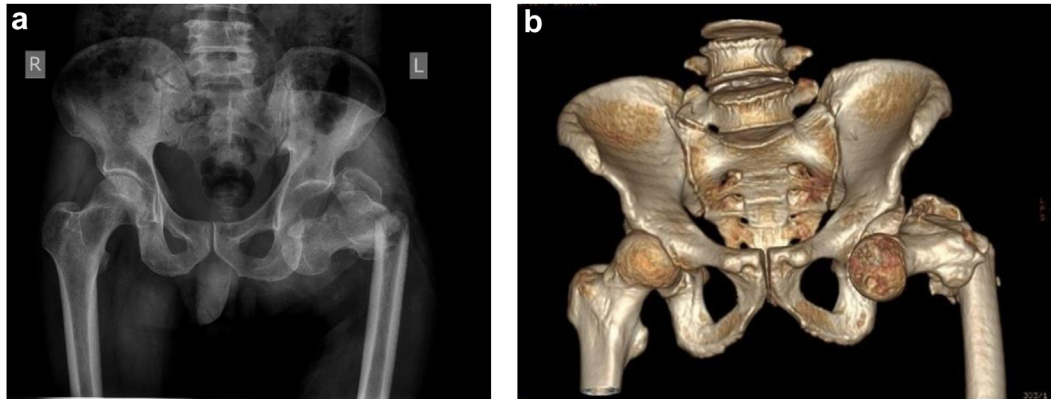


Figure 1. Radiological investigations showing femoral fracture with anterior hip dislocation. (a) Preoperative anteroposterior radiograph of pelvis. (b) Preoperative anteroposterior CT pelvis with 3D reformat.

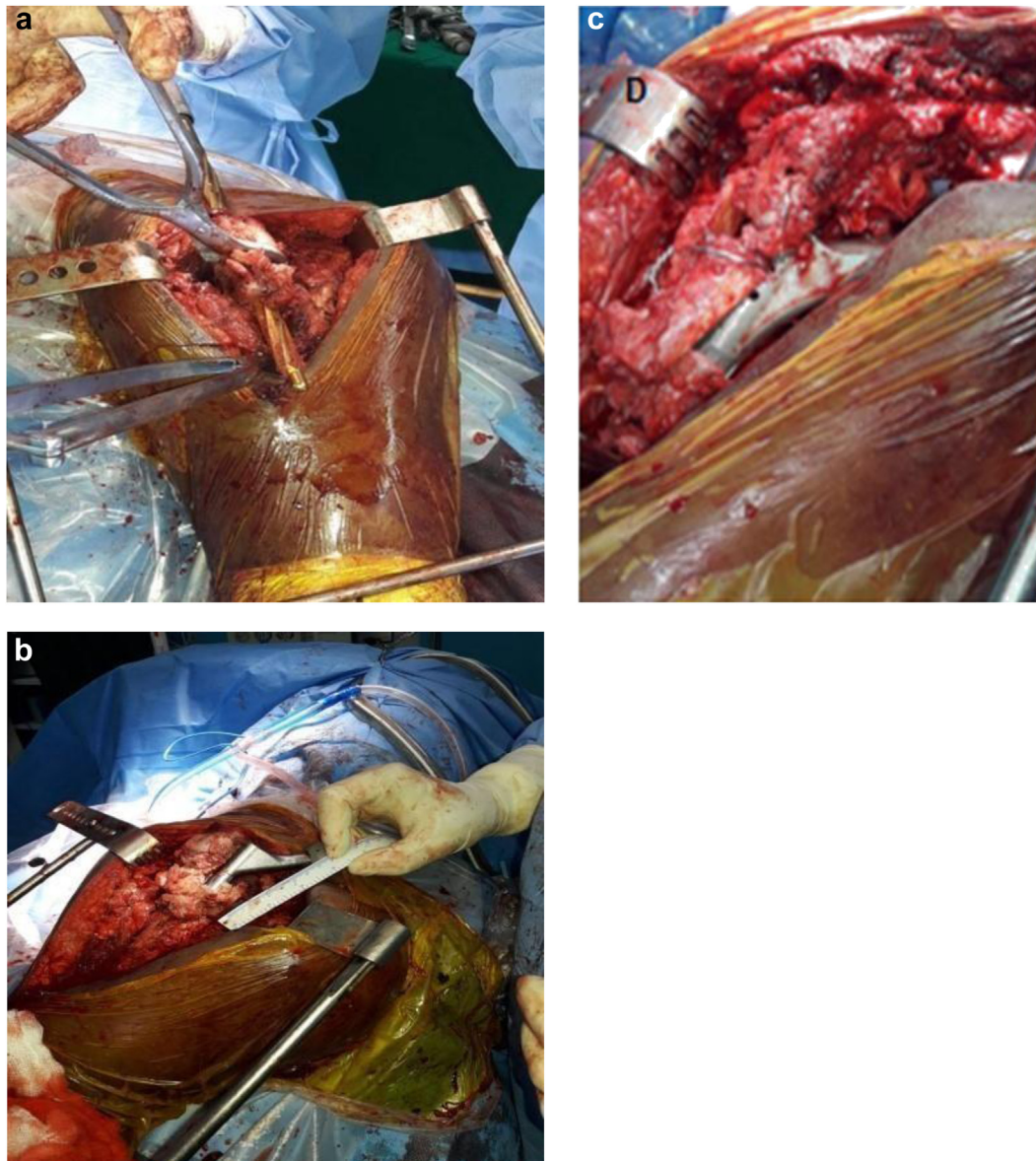


Figure 2. Intraoperative photographs. (a) Proximal and distal femur reaming with fragments held together with a bone clamp. (b) Deduction osteotomy. (c) Greater trochanter tension band wiring (TBW) performed with abductors.

replacement using a mega prosthesis, were discussed with the patient. Written informed consent was obtained after reviewing the risk and benefits of both alternatives, and the patient also provided consent for this article to be published.

After consultation with patient, THA with proximal femoral reconstruction was planned and performed. Under general anesthesia, the operation was performed using a standard posterior approach with the patient in the lateral position. The greater trochanter (GT) could not be palpated, so the incision was made at the level of the GT using fluoroscopic guidance. Exposure of the hip joint was difficult because of extensive adhesions and fibrosis. The sciatic nerve was identified and isolated. The pertrochanteric major fracture line was in the coronal plane, and multiple fragments with an atrophied abductor muscle mass were attached to the GT. Acetabular exposure was challenging because of extensive fibrosis; however, we managed to have an appropriate view of the acetabulum. The acetabulum was filled with fibrous tissue, which was resected very carefully. Upon examination, the acetabular wall was thin likely due to disuse osteopenia. Owing to the potential for iatrogenic acetabular fractures while impacting the cement-less cup, a cemented acetabular component was used. The comminuted proximal femur was approximated using a bone clamp, carefully handling the remnant abductor muscles attached to the bony fragments, and separate reaming for the proximal and distal femur was performed (Fig. 2a). The fragments were approximated and stabilized with Kirshner wires, ethibond sutures (Number 5 Ethibond; Ethicon Inc., Somerville, NJ) were passed through the fragments, and the muscle mass was approximated. Sequential reaming for the distal femur was performed, a trial stem was inserted, and reduction was attempted. However, owing to the tight proximal femoral muscles and abductors as well as stretching of the sciatic nerve, we could not reduce the trial implant. Therefore, the decision to perform a subtrochanteric femoral shortening osteotomy was made. After femoral shortening osteotomy of 1 cm, optimum tension of the sciatic nerve and reduction of the prosthesis were achieved (Fig. 2c). As we performed a transverse osteotomy, the rotational alignment of both the proximal and distal fragments was adjusted to allow approximately 10° – 15° of anteversion of the femoral component. Final preparation of the femur was undertaken, including repeated reaming to achieve optimal cortical contact, particularly distal to the osteotomy site, and a femoral component was inserted. There was extensive bone loss at the level of the GT on the posterior and medial aspects (Fig. 2c). The abductor muscles that had migrated proximally were attached to the neck of the prosthesis through the holes present in the Wagner SL Revision stem Zimmer (Warsaw, IN) and approximated with tension band wiring incorporating the abductor muscle mass (Fig. 2d). Grafts from the femoral head were used to fill the gap at the posterior and medial aspects of the proximal femur and were stabilized in the wiring. The stability of the hip was assessed in flexion, adduction, abduction, and internal rotation. A combined anteversion of approximately 45° was achieved as measured using a coplanar test. The Shuck test also demonstrated adequate tension in the abductor muscles. Closure was performed in layers, and a standard suction drain was used. Finally, the contractures of the adductor tendons were assessed, and an adductor tenotomy was performed to lengthen involved structures. There was no leg length discrepancy and no neurovascular deficit noted postoperatively.

Limb length discrepancy was managed with implant offset and correcting the center of rotation of the hip. The postoperative radiographs were judged satisfactory with a well-fitted distal stem (Fig. 3). Physiotherapy began on day 1 postoperatively and continued further. He was discharged with medication, including a subcutaneous injection of enoxaparin to prevent venous thromboembolism.

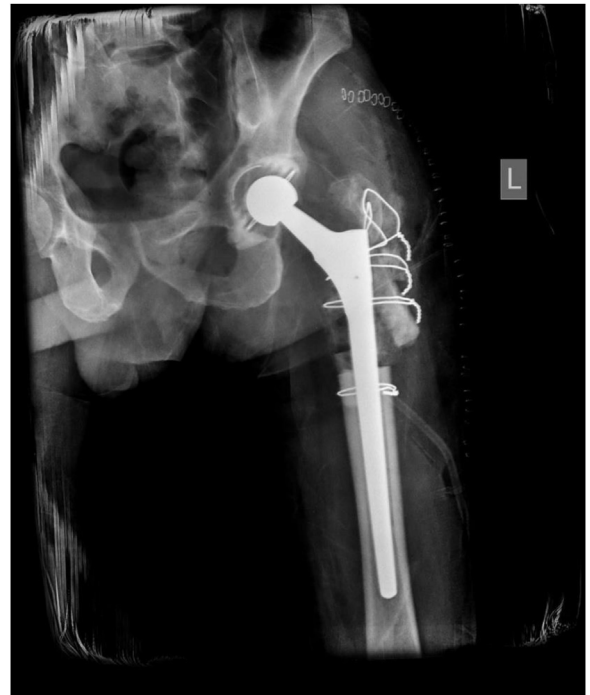

Figure 3. Immediate postoperative pelvis radiograph showing a satisfactory fit of the distally fitted uncemented femoral stem.

At the first follow-up 6 weeks postoperatively, hip movements were pain-free. The radiographs showed signs of osteointegration and well-fixed implants (Fig. 4a). Assisted partial weight-bearing was advised at this time. Serial follow-ups were performed at 3 months, 6 months, 9 months, 1 year, and 2 years and showed good osteointegration (Fig. 4b), a stable hip, and appropriate range of motion. The patient was cleared for full weight-bearing ambulation with the help of a walker at the end of 3 months. The radiographs at the 2-year follow-up (Fig. 4c) showed a broken wire and consolidation of the bone at the fracture and osteotomy site.

The functional status of the patient improved at each follow-up, and the Harris-Hip score improved from 10 (preoperatively) to 40 (6 weeks), 58 (3 months), 72 (6 months), 79 (9 months), 81 (1 year), and 89 (2 years) postoperatively. He had no pain and no leg length discrepancy but demonstrated minimal lurch with ambulation.

Discussion

Hip dislocation is a time-sensitive medical emergency and must be addressed immediately (within 6 hours) to prevent future complications such as avascular necrosis or secondary osteoarthritis [6]. However, a delay of more than 3 months leaves the surgeon with minimal choices. Although THA is a good option in such cases, some authors report the use of subtrochanteric osteotomy, the Girdlestone procedure, hip arthrodesis, or hemiarthroplasty [1]. The optimal treatment for such neglected cases of hip dislocations is still controversial. In addition, anterior dislocations are quite rare compared with posterior dislocations [5]. Ours is a unique case, as the patient presented with associated comminuted pertrochanteric femur fracture with anterior hip dislocation and successful radiological and clinical performance 2 years postoperatively. To the best of our knowledge, this is the first such case reported in the literature.

Neglected hip dislocations are rare, but some reports are available in the literature. Kumar and Jain [7] treated 18 children with

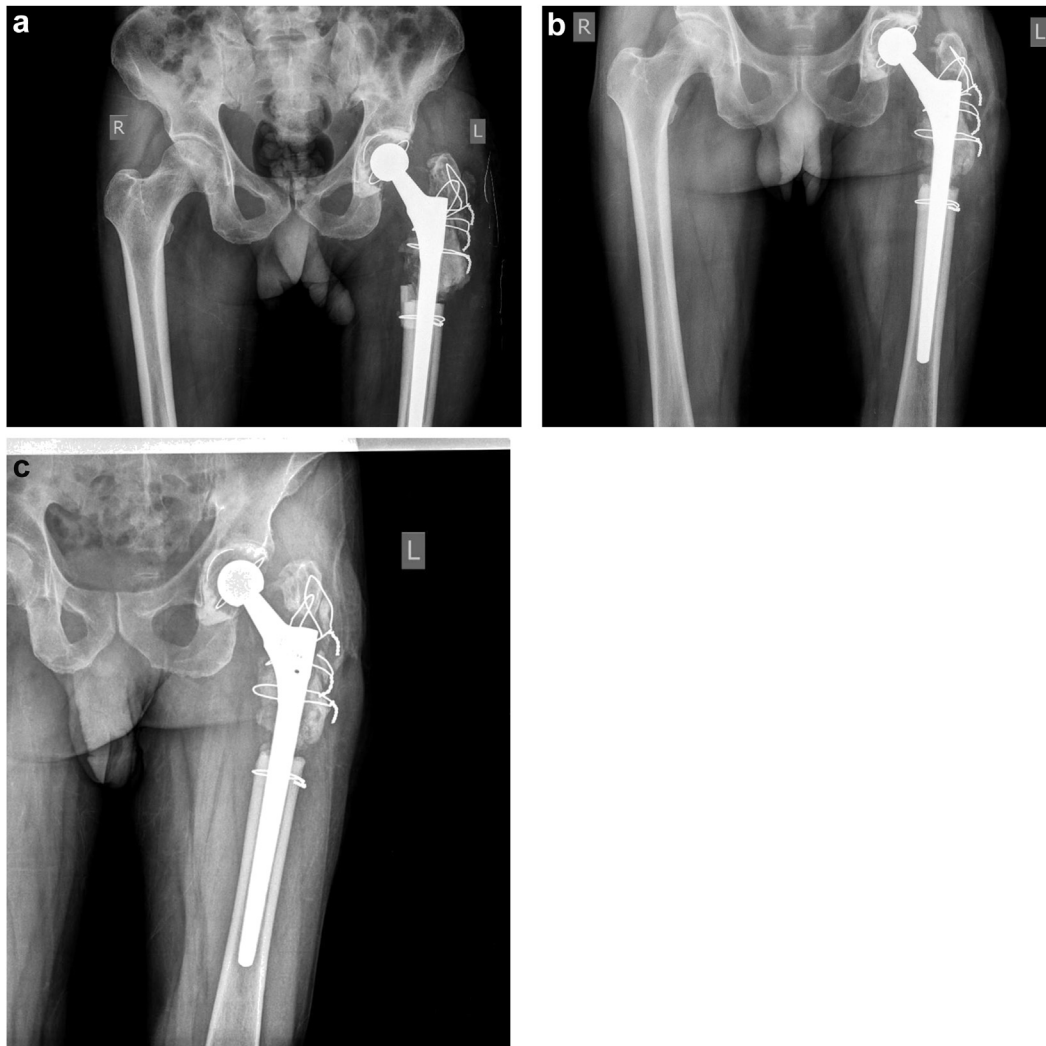

Figure 4. Follow-up pelvis radiographs showing good osteointegration and gradual bony union. (a) Postoperative anteroposterior radiograph at the end of 6 weeks. (b) Postoperative anteroposterior radiograph after 1 year. (c) Postoperative anteroposterior radiograph after 2 years.

neglected posterior traumatic hip dislocation by open reduction after skeletal traction. They found excellent outcomes in 17 children despite varying degrees of avascular necrosis [7]. In a study of 755 constrained THAs, 10% were primary hip replacements in patients with abductor dysfunction that reported promising results. This indicates constrained THA can be a viable alternate surgical choice with abductor dysfunction [8]. A 5-month-old anterior hip dislocation was treated with a modified girdle stone operation by Alva et al. [3]. The patient had a relatively stable hip with a satisfactory range of motion. Furthermore, Kumar et al. [1] successfully treated 2-year-old hip dislocation by THA with subtrochanteric osteotomy.

Considering the extensive abductor muscle fibrosis in this case, a dual mobility cup in an uncemented press-fit acetabular component was a viable option (The cemented version was not available during the study period.). In this case, a cemented cup was not considered an option because of the age of this patient; however, intraoperatively, the reaming surgeon found that the bone quality was poor because of disuse osteopenia (secondary to disuse joint function), so we altered our plan from an uncemented to a cemented cup. In this situation, if we had fixed with an uncemented cup, it would have had a significantly higher chance of failure due to poor bone quality and less bony growth. Van Praet F and Mulier [9]

showed the 15-year survivorship of cemented acetabular cup fixation in young and old individuals.

The abductors were atrophied as a consequence of delay in the treatment; however, no abductor reconstruction was required after reduction as adequate tension was achieved in the abductors. Whiteside [10] described gluteus maximums muscle transfer in complete destruction of the abductor muscles which appears to be an effective remedy for much of the disability caused by the loss of the abductor muscles.

Proximal femoral bone deficiency was addressed using diaphyseal fitting (Wagner SL Revision stem Zimmer, Warsaw, IN) cement-less stems, which do not rely on proximal femoral bone structure. As the fracture line was in the coronal plane and multiple small bony fragments in different planes were not amenable for plate and screw fixation, we found no advantage of use of the claw plate over stainless steel wire fixation for the reconstruction of GT and proximal femur. New bone formation was observed with good osteointegration at periodic follow-ups in this case. A prior study has shown encouraging results in treating bone deficiencies in the proximal femur using a Wagner SL Revision stem with impaction bone grafting. These results may be due to the proximal transmission of force due to the prosthesis's conical shape, higher

elasticity of the titanium alloy, and/or good histocompatibility of the rough-blasted surface [11].

Our case presents an example of reverse hybrid fixation, that is, using a combination of a cemented polyethylene cup and an uncemented femoral stem. A 10-year follow-up study from the Norwegian Arthroplasty register has shown promising results for certain reverse hybrid total hip replacements [12].

The patient in our case showed improvement of the Harris-Hip score from 10 (preoperatively) to 89 (2 years postoperatively). He showed minimal lurch with ambulation and no leg-length discrepancy.

Summary

Surgeons can encounter complex, rare cases. Thus, they should plan meticulously and execute accordingly. In the present case of a 7-month-old anterior hip dislocation with comminuted femoral fracture, the surgeon was confronted with several challenges including proximal femoral reconstruction, reduction osteotomy, and abductor muscle mass atrophy. The patient was treated with THA with a revision stem along with bone grafting. This procedure successfully achieved a painless and mobile hip joint 2 years postoperatively. However, we still suggest confirming the results of this procedure via long-term, periodic follow-up.

Conflicts of interest

The authors declare that they have no known competing financial interests or personal relationships that could have appeared to influence the work reported in this article.

Acknowledgments

The authors would like to acknowledge their team especially the ORP Mr. Shailesh, anesthetist Dr. Anu Narayan, Trauma team support Dr. Ashok Singh and the OT team. They also thank Dr. Rabindra Narain Singh.

Informed patient consent

The author(s) confirm that informed consent has been obtained from the involved patient(s) or if appropriate from the parent, guardian, power of attorney of the involved patient(s); and, they have given approval for this information to be published in this case report (series).

References

- [1] Kumar S, Dahuja A, Narula MS, Garg S, Kaur R. Neglected hip dislocation: an unusual presentation, its management and review of the literature. *Strateg Trauma Limb Reconstr* 2017;12(3):189.
- [2] Dawson-Amoah K, Raszewski J, Duplantier N, Waddell BS. Dislocation of the hip: a review of types, causes, and treatment. *Ochsner J* 2018;18(3):242.
- [3] Alva A, Shetty M, Kumar V. Old unreduced traumatic anterior dislocation of the hip. *BMJ Case Rep* 2013;2013.
- [4] Garrett JC, Epstein HC, Harris WH, Harvey Jr JP, Nickel VL. Treatment of unreduced traumatic posterior dislocations of the hip. *J Bone Joint Surg Am* 1979;61(1):2.
- [5] El Masry AM. Anterior hip dislocation with ipsilateral displaced fracture neck of femur treated by open reduction and internal fixation: case report and review of the literature. *Strateg Trauma Limb Reconstr* 2017;12(3):205.
- [6] Gokulprasath S, Tarun Prashanth K. Anterior hip dislocation with ipsilateral subtrochanteric femur fracture in a young adult – a rare case report. *J Orthop Case Rep* 2020;10(3):63.
- [7] Kumar S, Jain AK. Neglected traumatic hip dislocation in children. *Clin Orthop Relat Res* 2005;431:9.
- [8] Berend KR, Lombardi Jr AV, Mallory TH, Adams JB, Russell JH, Groseth KL. The long-term outcome of 755 consecutive constrained acetabular components in total hip arthroplasty examining the successes and failures. *J Arthroplasty* 2005;20(7 Suppl 3):93.
- [9] Van Praet F, Mulier M. To cement or not to cement acetabular cups in total hip arthroplasty: a systematic review and re-evaluation. *SICOT J* 2019;5:35.
- [10] Whiteside LA. Surgical technique: transfer of the anterior portion of the gluteus maximus muscle for abductor deficiency of the hip. *Clin Orthop Relat Res* 2012;470(2):503.
- [11] Singh SP, Bhalodiya HP. Results of Wagner SL revision stem with impaction bone grafting in revision total hip arthroplasty. *Indian J Orthop* 2013;47(4):357.
- [12] Lindalen E, Havelin LI, Nordsletten L, et al. Is reverse hybrid hip replacement the solution? *Acta Orthop* 2011;82(6):639.