



## A Comparison of Functional Outcome Following Conservative or Operative Treatment of Intra-Articular Fractures of Calcaneum

**Ashish Singh\*, Purushotam Kumar, Kartheek Telagareddy, Sushil Sing, Pankaj Kumar, Rabindra Narain Singh, Ashok Singh, Abhishek Kumar, Arjun Jayaraj, Rishabh Kumar Singh and Pravez Anwar**

*Department of Orthopedics, Anup Institute of Orthopedics and Rehabilitation, Kankarbagh, Patna, Bihar, India*

**\*Corresponding Author:** Ashish Singh, Department of Orthopedics, Anup Institute of Orthopedics and Rehabilitation, Kankarbagh, Patna, Bihar, India.

**Received:** May 02, 2022

**Published:**

© All rights are reserved by **Ashish Singh, et al.**

### Abstract

**Aim:** A comparative to study the functional outcome in Intra-articular Fractures of Calcaneum after Surgery and conservative management.

**Materials and Methods:** A prospective short-term study was conducted to compare Functional outcome in Intra -Articular Fractures of Calcaneum after Surgery and conservative management from December 2015 to December 2017.

All patients with intra-articular fractures of the Calcaneum that confirmed to the inclusion criteria were included in the study. Patients were investigated with plain radiography and CT scan. X-ray included Calcaneum lateral and axial views. Bohler's angle was calculated and Geographic pattern of the fracture was studied and classified using Essex Lopresti classification.

All patients were treated initially using a posterior slab and limb elevation before definitive management. Following which patients were treated conservatively which included below knee cast application. The Operative Treatment protocol included either Essex Lopresti Maneuver or Open reduction and internal Fixation with a reconstruction plate, depending upon the surgeon. All surgeries which were done aimed to restore the Bohler's angle and were done by single surgeon patients were given a below knee cast after subsidence of swelling and were mobilized non weight bearing with axillary crutches or a walker for a period of 6 weeks and gradual weight bearing mobilization was allowed until Union.

Bohler's Angle was calculated post operatively and functional outcome was assessed at 12 weeks, 3 months, 6 months and 1 year and 6 monthly respectively. The results were evaluated with the Ankle and Foot Society Scoring System and reviewed. SF 36 questionnaires were filled at the end of the study.

**Observation and Results:** A total of 26 patients were reviewed. According to the AOFAS scale, 63.6% all patients developed good and fair results. The SF 36 Score this present study suggested better quality of life in the operated group ( $p = 0.011$ ) which was statistically significant at the end of two years.

**Conclusion:** All displaced intra- articular fractures of Calcaneum should be treated with anatomical reduction and restoration of the Bohler's angle so to have a better and early functional outcome.

**Keywords:** Functional Outcome; Conservative; Operative; Intra-Articular Fractures; Calcaneum

## Introduction

Calcaneum fractures are the most common fracture of the tarsal bones, yet controversy still exists on the best treatment for these disabling injuries [1-14]. These fractures result due to axial loading of the Calcaneum, that is, fall from height, and therefore, many of these are bilateral or associated with pelvic or vertebral fractures [20-22]. Conservative management of these fractures almost always leads to continuing disabling pain and stiffness. Consequently, many operative procedures are preferred for the treatment of calcaneal fractures, including percutaneous screw fixation, open reduction, and plating with reconstruction plates as well as fixation with locking anatomical plates. Historically, most calcaneus fractures have been treated closed because open reduction and internal fixation did not result in improved outcomes and had high complication rates (Bankart) [2]. However, as a better understanding of fracture patterns with computed tomography (CT) scans and modern surgical techniques and hardware, has resulted in improved outcomes and lowered morbidity. We undertook a prospective case series analysis in an effort to compare operatively treated to conservatively treated patients with intra-articular fractures of calcaneum.

Calcaneum fractures are classified into two way intra-articular and extra-articular fracture with involvement of subtalar joint. Intraarticular fracture further classified by Essex-Lopresti [15] (1952) into joint depression- and tongue type fractures.

On plain radiograph, when the fracture line exits behind the posterior facet and anterior to attachment of Achilles tendon, it is called joint depression-type fracture. Tongue-type fracture is one in which there is a secondary fracture line which exits distal to Achilles tendon attachment, and the articular fragment remains attached to the tuberosity fragment [23,24]. A further detailed descriptive classification was given by Sanders [25,26]. Based on axial view computed tomography (CT) scan. According to this classification, un-displaced fractures are classified as Type I. Type II is further classified into IIA, IIB, and IIC based on the location of the primary fracture line. Type III is classified into IIIAB, IIIBC, and IIIAC. Comminuted fractures are classified as Type IV.

This present study aims at a Comparison of functional outcome following conservative or operative Treatment of Intra-Articular Fractures of Calcaneum.

## Materials and Methods

The objective of this prospective study was to evaluate the clinical and functional outcome in surgical treatment and conservative treatment of intra-articular fractures of Calcaneum. The study was conducted at Anup institute of orthopedics and Rehabilitation, Patna, India. Ethical committee approval and informed consent was taken prior to the start of the study. Period of study was from April'2015 to December'2017. Inclusion criteria were patients above 13 years of age, intra-articular fractures and exclusion criteria were compound injuries, bilateral calcaneal fractures, pathologic fractures, and patients with neuromuscular disorders.

All patients were initially treated with a posterior below knee slab followed by definitive treatment. The conservative treatment protocol involved applying a below knee cast for about 8 weeks. At 8 weeks, after removal of the cast, the patients were clinically and radiologically assessed for signs of union of the fracture, evidence of mal-union based on the Bohler's angle [15] and angle of Gissane [17]. Strict non weight bearing mobilization and passive Range of movement was initiated at 8 weeks. Weight bearing was started after 12 weeks.

The operative treatment protocol included either Essex Lopresti Maneuver [16] or open reduction and internal fixation with a reconstruction plate. All surgeries aimed to restore the Bohler's angle [15] and were performed by a single surgeon. All patients who were operated by open reduction and internal fixation was as done by using Benirsche and Sangeorzan incision [18] (lateral extensile approach). Iliac crest bone grafting was done in the required cases. Strict limb elevation was requested in all cases.

## Post-operative care

Wound was dressed on the 3rd postoperative day, and sutures were removed after 10-14 days. Non weight bearing mobilization was allowed after 2nd post-operative day. Post operatively, a cast for 6 weeks was given after suture removal. Weight bearing mobilization was advised after 10 weeks depending on the assessment which was followed by partial weight bearing mobilization and physiotherapy. In all the post-operative cases the Bohler's angle [15] was calculated and compared with the pre-operative Bohler's angle [15].

## Results

We undertook a prospective case series analysis in an effort to compare operatively treated to conservatively treated patients with intra-articular fractures of calcaneum. This study included 26 patients, 23 Males (88.5%) and 3(11.5%) females. The majority of the patients were in the active age group that is 20 to 40 years. The mechanism of injury was as a result of a fall from a height in 69.2% cases, while 30.8% were associated with road traffic accidents. According to the Essex-Lopresti [15] scale 20 patients (76.9%) were joint-depression type and 6 patients (23.1%) tongue-kind. The treatment modality was based on the admission of trauma units, one of which purely opted for conservative treatment while the unit routinely performed a surgical procedure to restore the Bohler's angle [15]. The mean follow up was 26.3 months. The outcome was evaluated using the American Orthopedic Foot and Ankle Society Ankle hindfoot scale of Foot and Ankle Surgeons (A.O.F.A.S.) [19] score at 3months, 6months, 9months, 1 year and 2year respectively and SF 36 questionnaire was completed at the end of two years to ascertain the post trauma status. We have tried to compare the functional outcome between the operative and the non-operative group in this present series. Early complications were present in 15.38% of the patients; the most common ones were infections in the operative group. Late complications were identified in 57.3% of the patients, the most common ones being residual edema and heel pad pain. The incidence of late complications was not related to the type of fracture. The Bohler's angle [15], postoperatively measured, showed a direct relationship with the final outcome, and angles smaller than 20 degrees determine a greater incidence of poor results ( $p = 0.01$ ). According to the A.O.F.A.S [19] scale, 63.6% all patients developed good and fair results. The SF 36 Score in this present study suggested better quality of life in the operated group ( $P = 0.01$ ) which was statistically significant at the end of two years.

The patients were evaluated using the A.O.F.A.S [19] score at 3months, 6months, 9months, 1year and 2year respectively and X-rays. X-ray result of surgical treatment was provided by the assessment of postoperative Bohler's angle [15]. The results were clinically assessed by A.O.F.A.S [19] scale for ankle and hind foot, which takes the following items into consideration: pain intensity; function (activities restraint and need of support with orthotics); maximum distance of gait measured by blocks; gait abnormality; sagittal mobility (flexion extension); hindfootmobility (inversion+ eversion); ankle and hind foot stability (anteroposterior + varus-valgus) and foot and ankle alignment. Scores for each item were

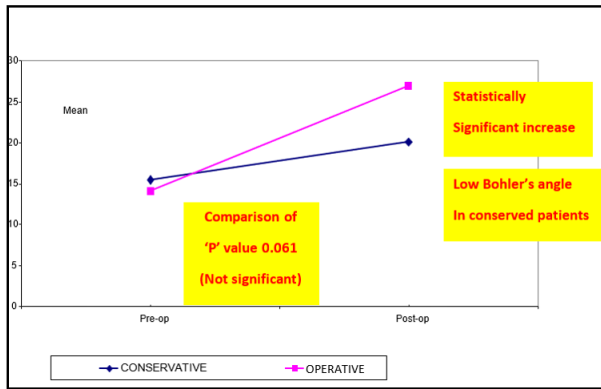
added, providing scores from 0 to 100. Results were considered as excellent when scores ranged from 90 to 100, good when between 80 and 89, fair when ranging from 70 to 79 and bad when scores from 69 and below. The return to work (or not) was also considered.

The SF 36 questionnaire was filled at the end of 2 years that is after the completion of the study and was compared with the SF 36 questionnaire which was requested to be filled immediately on their first visit relating their pre-injury functional level. Statistical methods used were "unpaired Student's t-test to compare continuous numeric data," " $< CHI > 2$  analyses for categorical data," and that "statistical significance was defined at the 5% ( $P = 0.05$ ) level."

Among the 26 patients followed up, we could notice a prevalence of males. Ages ranged from 17 to 60 years, with a mean of 39.6 years. Falls from different levels were the mechanism accounting for 18 fractures (69.2%). Rest 8 patients (30.8%) were victims of road traffic accidents. 69.2% presented with only calcaneus fractures while 30.8% had other injuries: femoral fracture, knee fracture, lumbar spine fracture, radius fracture, and elbow fracture. Located at the left calcaneus were 10 cases (38.5%) and 16 at the right calcaneus (61.5%). X-ray study allowed for the classification of fractures, according to Essex-Lopresti [16] which revealed 20 cases of Essex Lopresti joint depression type (76.9%) and 6 were of tongue type (23.1%).

From the 26 patients, 15 patients (57.6%) were conservatively managed and 11(42.3%) received surgical treatment. Amongst the 11 cases which were operated, 5 patients (19.2%) were operated with open reduction and internal fixation with a reconstruction plate whereas 6 patients (23%) underwent Essex Lopresti maneuver [16].

The Bohler's angle [15] calculated in both the groups showed a mean Bohler's angle [15] of 15.4 degrees in the conservative group with a standard deviation of 10.8 degrees whereas in the operative group mean preoperative Bohler's angle was 14.1 with standard deviation of 6.1. The post-operative Bohler's angle mean was 26.9 degrees with standard deviation of 10.2. Pre-operative Bohler's angle [15] and post op Bohler's angle [15] was statistically significant in the operated group, whereas it was not significant statistically between the operative and the non-operative group ( $P$  value 0.061) (Figure 1).



**Figure 1:** Line Diagram Showing Post Operative Change In B-angle. Comparison between Conservative and Operative Procedures.

Complications were as early complications which were present in 15.38% of the patients; the most common ones were infection and spreading cellulitis. Late complications were identified in 57.3% of the patients, the most common ones being residual edema and heel pad pain. Subtalar arthritis developed in 5 patients (19.23%) The incidence of late complications was not related to the type of fracture.

As per the A.O.F.A.S [19] (Table 1) Score the score increased with time in months and the functional score was better in the operative group {mean A.O.F.A.S [19]. score tabulated} but this was insignificant statistically with a 'P' Value of 0.05.

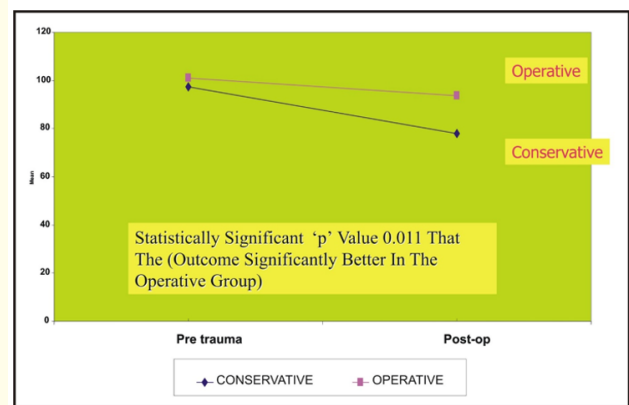
	Three Months	Six Months	Nine Months	Twelve Months	Twenty-Four Months
Conservative	40.6	49.8	66.8	75.27	80.33
Operative	46.18	56.73	69.18	77.64	87.73

**Table 1:** Showing Mean A.O.F.A.S. [19] over Time in Months between Operative and Non-Operative Group.

The classification of outcomes according to A.O.F.A.S [19] scale allowed for the recognition of 12 fractures (46.15%) evolving with good outcome, 4 cases (15.3%) as fair outcome and 6 cases (23%)

as Bad outcome and 4 cases (15.3%) with a poor outcome. Out of this we had 7 patients (63.6%) of the patient in operative group with good result and only 5 patients (33.33%) in the conservative group with the Good result. However this was statistically insignificant as the 'P' value is more than 0.05.

The SF 36 outcome (Figure 2) was statistically significant with a p value 0.011 which signifies that the outcome was definitely better in the operative group as compared to the conservative group (which was also statistically significant).



**Figure 2:** Post Operative Change in SF-36 Score, Comparison between Conservative and Operative Procedures.

The complication rate was definitely less as compared to other series. Early complications were present in 15.3% of the patients; the most common ones were infection and spreading cellulitis whereas late complications were identified in 57.3% of the patients, the most common ones being residual edema and heel pad pain. In one case early implant removal was done in view of infection.

However the exact reason for a better outcome could not be assessed. This could be attributed due to early mobilization as the majority of the patients were in the active age group that is between 20 years and 40 years. In our series all patients were able to return to work with a mean of 6.3 months.

### Discussion

Intra-articular fractures are common as compared to extra-articular fractures; hence there is importance of anatomical reduc-

tion to decrease the possibility of joint incongruity and subtalar arthritis. In the present series, joint depression variety was more common as compared to the tongue type. This observation matches with that cited by other author's also. Associated injuries were common, especially involving spine and lower limb, as was also noted by others. In our study, it was possible to restore the Bohler's angle post-operatively. The average mean pre op B.A. was 14.1 with standard deviation of 6.1. The post op B.A. mean was 26.9 degrees with standard deviation of 10.2.

Functional outcome is definitely better in the operative group and this, can be attributed to the correction of the Bohler's angle. In conclusion it is the author's group opinion that all displaced intra- articular fractures of the calcaneum should be treated with anatomical reduction and restoration of the Bohler's angle to have a better and early functional outcome. However, the limitations of this study included a small sample size and a better and detailed imaging modality like CT should have been done in every case.

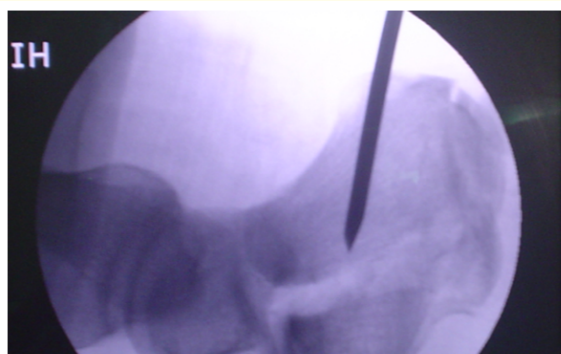
Management of intra-articular displaced calcaneum fracture has always been challenging for orthopedic surgeons. The ultimate goal is to achieve proper anatomical reconstruction and early rehabilitation without any complications. The best treatment of this fracture remains controversial. Various studies have been conducted to compare the functional outcomes of operative and conservative treatment for these fractures but controversy still exists. The present study was therefore conducted in a prospective manner to compare the functional outcomes of conservative versus operative treatment.

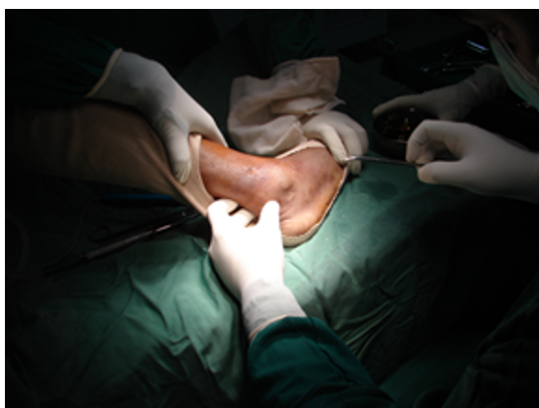
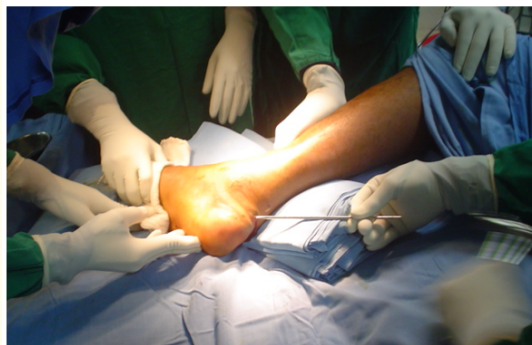
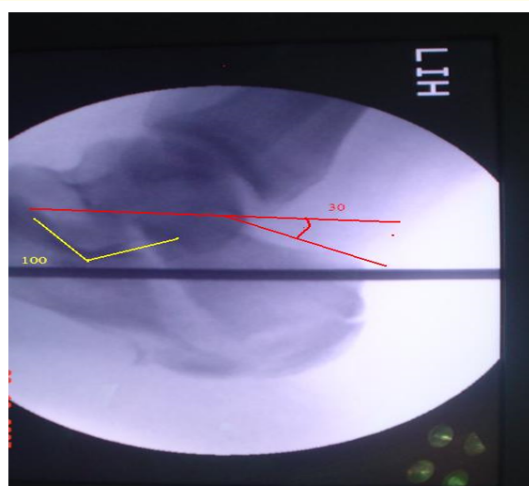
Figure 3: Position of the patient supine.



3a



3b



3c

Figure 3a-c: Showing Essex Lopresti maneuver. ORIF with K wires, cancellous Screws, AO Reconstruction Plate Bone grafting if required.

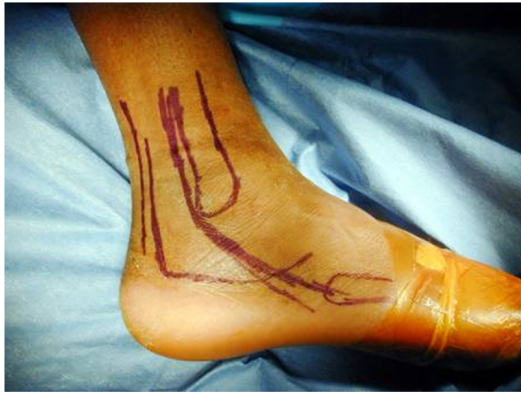

Figure 3d: landmark for incision line.

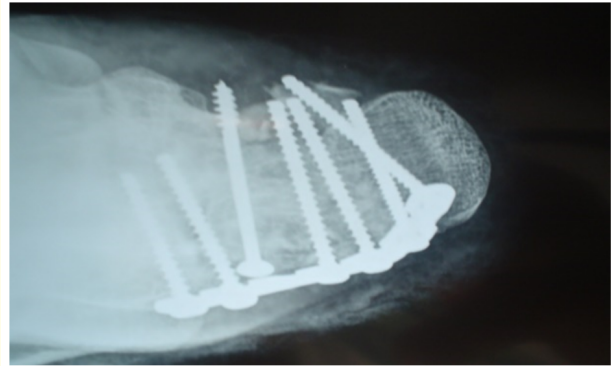


Figure 3g: AP Xray.

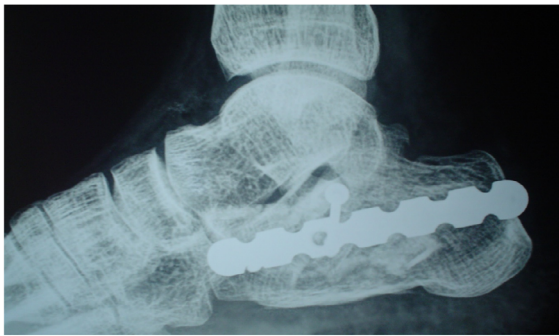


Figure 3f: Lateral Xray.

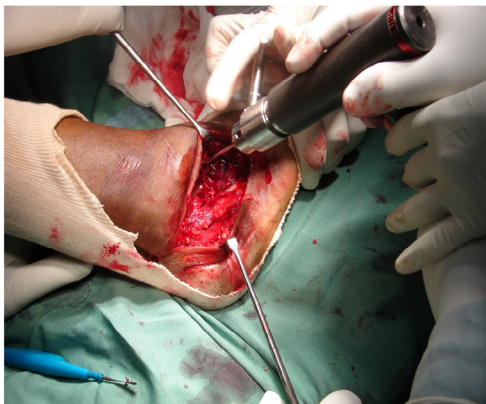


Figure 3e: Fixation of plate.

### Conclusion

All displaced intra-articular fractures of Calcaneum should be treated with anatomical reduction and restoration of the Bohler's angle so to have a better and early functional outcome. However the limitations of this study included a small sample size and a long term follow up.

### Bibliography

1. Cotton FJ and Wilson LT. "Fractures of the os Calcis". *The Boston Medical and Surgical Journal* 159 (1908): 559-565.
2. Bankart ASB. "Fractures of the os calcis". *Lancet* 2 (1942): 175.
3. Palmer I. "The mechanism and treatment of fractures of the calcaneus". *The Journal of Bone and Joint Surgery. American* 30 (1948): 2-8.
4. Stephenson JR. "Treatment of displaced intra-articular fractures of the calcaneus using medial and lateral approaches, internal fixation and early motion". *The Journal of Bone and Joint Surgery. American* 69 (1987): 115-130.
5. Soeur R and Remy R. "Fractures of the calcaneus with displacement of the thalamic portion". *Journal of Bone and Joint* 57 (1975): 413-421.
6. Parmar HV, et al. "Intraarticular fractures of the calcaneum treated operatively or conservatively: a prospective study". *Journal of Bone and Joint Surgery* 75B (1993): 932.

7. Thordarson DB, *et al.* "Calcaneal fractures. Foot and ankle". *American Academy of Orthopaedic Surgery* 2 (1998): 215-227.
8. Rndale., *et al.* "Should Fractures Calcaneum be conserved?" *A Meta-Analysis Clinical Orthopaedics CD 001* (2000): 161.
9. Petit Goff CW. "Fresh fracture of the so calcis". *The Archives of Surgery* 36 (1938): 744-765.
10. Cotton FJ and Wilson LT. "Fractures of the oscalcis". *The Boston Medical and Surgical Journal* 159 (1908): 559-565.
11. Magunson and Wilson PD. "Treatment of fractures of the oscalcis by arthrodesis of the subastragalar joint". *JAMA* 989 (1927): 1676-1683.
12. Wilson JN. "Watson-Jones fractures and joint injuries, 5<sup>th</sup> edition". Edinburgh: Churchill Livingstone (1976).
13. Wilson PD. "Treatment of fractures of the oscalcis by arthrodesis of the subastragalar joint". *JAMA* 989 (1927): 1676-1683.
14. Pendulum fractures of the oscalcis". *Clinical Orthopaedics* 83:214,
15. Böhler L. "Diagnosis, pathology, and treatment of fractures of the oscalcis". *The Journal of Bone and Joint Surgery* 13 (1931): 75-89.
16. Essex-Lopresti P. "The mechanism reduction technique, and results in fractures of the oscalcis". *British Journal of Surgery* 39 (1952): 395-419.
17. Gissane W. "Proceedings of the British Orthopedics Association". *The Journal of Bone and Joint Surgery* 29 (1947): 254-255.
18. Benirschke SK and Sangeorzan BJ. "Extensive intra-articular fractures of the foot". *Clinical Orthopaedics* 292 (1993): 128-134.
19. Kiatoka HB, *et al.* "Clinical Rating System for the Ankle -Hind-foot, midfoot, and lesser toes". *Foot and Ankle International* 15 (1994): 349-353.
20. Fitzgibbons TC, *et al.* "Fractures and dislocations of the calcaneus. In: Bucholz RW, *et al.* "Rockwood and Green's Fractures in Adults. 5<sup>th</sup> edition". 3. Philadelphia: Lippincott Williams and Wilkins (2001): 21332179.
21. Pendse A, *et al.* "Outcome after open reduction and internal fixation of intraarticular fractures of the calcaneum without the use of bone grafts". *Indian Journal of Orthopaedics* 40 (2006): 111114.
22. Raymakers JT, *et al.* "Results after operative treatment of intraarticular calcaneal fractures with a minimum followup of 2 years". *Injury* 29 (1998): 593599.
23. Mostafa MF, *et al.* "Surgical treatment of displaced intraarticular calcaneal fracture using a single small lateral approach". *Strategies in Trauma and Limb Reconstruction* 5 (2010): 8795.
24. Varela CD, *et al.* "Fracture blisters: Clinical and pathological aspects". *Journal of Orthopaedic Trauma* 7 (1993): 417427.
25. Sanders, *et al.* "Operative treatment in 120 displaced intraarticular calcaneal fractures. Results using a prognostic computed tomography scan classification". *Clinical Orthopaedics and Related Research* 290 (1993): 8795.
26. Sanders R. "Intraarticular fractures of the calcaneus: Present state of the art". *Journal of Orthopaedic Trauma* 6 (1992): 252265.