



Case Report

Formosan Journal of Musculoskeletal Disorders 13 (2022) 143-148
DOI:10.6492/FJMD.202208_13(3).0006

Our experience with extended trochanteric osteotomy: a saviour in revision hip arthroplasty

Ashish Singh*, Kartheek Telagareddy, Purushotam Kumar, Sushil Singh, Rabindra Narain Singh, Abhishek Kumar

Department of orthopaedics, Anup Institute of Orthopaedics and Rehabilitation, Patna, Bihar, India

Keywords:

extended trochanteric osteotomy, revision total hip replacement, hip Joint, hip stability, aseptic

ARTICLE INFO

Article history:

Received 17 January 2022
Received in revised form
28 April 2022
Accepted 15 May 2022

*Corresponding author

Anup Institute of Orthopaedics and Rehabilitation
Kankarbagh, Patna 800020, India
Tel: +91-8294240349
E-mail: drashishsingh@hotmail.com
(A. Singh)

ABSTRACT

Introduction: Despite the overwhelming success and long term reliability of total hip arthroplasty (THA), several situations necessitate the revision of femoral component. The use of extended trochanteric osteotomy (ETO) is a method that allows exposure of the proximal femur through the use of controlled cortical fracture.

Purpose: This surgical technique is extremely helpful to facilitate the removal of a well fixed femoral implant, to provide increased surgical exposure and to permit concentric placement of a new implant. Familiarity with this surgical technique is crucial for surgeons who frequently perform revision THA.

Methods: This was a retrospective study of 31 revision hip arthroplasties with a proximal femur ETO performed from 2014 to 2017 by a single surgeon using posterolateral approach and to describe the radiological and functional outcomes with an emphasis on intra-operative difficulties and surgical time.

Results: The mean Harris hip score increased from 40 pre-operatively to 90 at the final follow-up. Solid bony union was observed on all post-operative radiographs within 6 months. There was no displacement of osteotomised fragments, positions of fixation cables were unchanged, and there was no metallic wire/cable loosening or bone reaction around the wires. Complete ETO union was noted in one case where a plate was used because of iatrogenic fracture of the medial wall

Conclusion: ETO is a safe and very useful technique that can be used in revision hip surgery. When performed carefully and repaired meticulously using cables or wires and supported by autologous bone graft, it results in reliable union with relatively infrequent complications.

1. Introduction

Femoral component removal is commonly required during revision for total hip arthroplasty (THA) or partial hip arthroplasty. The key principles of safe and successful stem removal involve careful preoperative planning, adequate exposure, dedicated instruments, proper technique and patience. Instruments specifically intended for extraction are strongly recommended to extract a stable and well-fixed femoral implant, including flexible osteotomes, high-speed burr with a pencil tip, hollow trephine, ultrasonic cement plug pullers, handheld fibre optic light source, specially designed suction tip and grasping devices. Maintaining this instrumentation imposes an economical burden in hospitals in developing countries. Even with sophisticated instrumentation, revision hip surgeons often encounter complications such as iatrogenic fracture, perforation, prolonged operative time, and failure to remove the implant.

The purpose of this study is to describe the radiological and functional outcomes following extended trochanteric osteotomy (ETO) for a single-surgeon series with an emphasis on intra-operative difficulties and surgical time.

2. Case Report

This was a retrospective study of 31 revision hip arthroplasty with a proximal femur ETO performed from 2014 to 2017. The patient demographics are described in Table 1. There were 16 males and 15 females. The average age at revision was 59.9 years (range, 37–80 years), and the average body mass index was 26.4 (range, 18–30). The average time interval from index surgery to the revision was 7.2 years (range, 1–25 years). Indications for revision were aseptic loosening ($n = 14$), peri-prosthetic joint infection ($n = 2$), peri-prosthetic fracture ($n = 1$), femoral implant breakage ($n = 12$), and others ($n = 2$). The mean operative time was 110 min (range, 100–140 min). Among 31 procedures, we extracted 21 cemented and 10 cementless stems. All patients underwent osteotomy site reconstruction with a combination of cables (Control Cable Sleeve-Cobalt Chrome 1.8 mm X 24") and metallic wires (Depuy Synthes® stainless steel cerclage wire 1.25 mm). All patients were followed for a minimum of 2 years to assess clinical and radiological outcomes.

All procedures were performed via the posterior approach. Following exposure of the hip and proximal femur, an osteotomy line was marked with a diathermy. Holes were drilled with a 2.5 mm bit along the projected line, beginning at the base of the greater trochanter in the

Table 1. patient demography, level of ETO done, complications, implant name, and indications

	Value
Patient Demography	
Male, n (%)	16 (51.6)
Female, n (%)	15 (48.3)
Mean age at revision in years	59.9 (37–80)
Mean BMI	26.4 (18–30)
Interval between surgery and revision in years	7.2 (1–25)
Level of ETO	
Till the tip of cement, n (%)	21 (67.7)
Up to isthmus, n (%)	6 (19.3)
Tip of implant, n (%)	4 (12.9)
Intra op complication	
Fracture of the medial cortex at subtrochanteric level, n (%)	2 (6.4)
Extension of osteotomy, n (%)	1 (3.2)
None, n (%)	25 (80.6)
Post op complication	
Subsidence (5–10mm), n (%)	2 (6.4)
Implant name	
Wagner self-locking stem (Zimmer, Warsaw, IN, USA), n (%)	16 (51.6)
Solution stem (DePuy, Warsaw, Indiana, USA)	11 (35.4)
DePuy Synthes CORAIL Hip System, n (%)	2 (6.4)
Restoration Modular Stem*; Stryker Orthopaedics, Mahwah, NJ, n (%)	2 (6.4)
Preoperative Implant Fixation Method	
Cemented, n (%)	21 (67.7)
Uncemented, n (%)	10 (32.2)
Indications for revision	
Aseptic loosening, n (%)	14 (45.1)
Implant breakage, n (%)	12 (38.7)
Septic loosening, n (%)	2 (6.4)
Peri-prosthetic fracture, n (%)	1 (3.2)
others, n (%)	2 (6.4)

ETO, extended trochanteric osteotomy; BMI, body mass index; Intra op, intra-operative.

sagittal plane and extending distally, just anterior to the linea aspera. Osteotomy was performed using an oscillating saw reaching the tip of the implant in cementless stems and up to the level of cement restrictor in cemented stems from tip of greater trochanter (Fig. 1 A–D). We use malleable osteotome for debonding of bone metal interface over

medial side. The osteotomy was carried distally to the implant tip to allow for full exposure and easy implant removal. When this point was reached, the osteotomy was continued antero-laterally for a distance of one-third of the femoral circumference. The osteotomy was then opened based on an antero-lateral hinge of periosteum and muscle. The surgeon attempted to keep anterior soft tissue attached to the osteotomised fragment. Before revision stem implantation, the metallic wire was applied distal to the osteotomy site to prevent femoral shaft fracture propagation. An additional plate was used in cases of intra-operative fracture of the osteotomised fragment. All cases had distal fitting of rough blasted cementless long stems except 2 patients who were managed with cementless, tapered, fully hydroxyapatite-coated titanium stem. The types of implants used are described in (Table 1). The osteotomy fragment was re-approximated back into its bed in the lateral femur. A common error is to re-approximate the fragment too anteriorly, which can result in anterior impingement and posterior dislocation. Good re-approximation can be aided by abducting the leg and internally rotating the femur during osteotomy reconstruction. The posterior limb of the osteotomy should be re-approximated, leaving any longitudinal gap anteriorly. Once reduced, two to four wires/cables were passed around the diaphysis and trochanter fragment. It is critically important to pass the wires sub-muscularly to avoid injuring the vascular supply to the osteotomy site. They are

generally passed from the posterior to anterior direction to avoid sciatic nerve injury. The proximal cable was placed just distal to the lesser trochanter, and one additional cable was placed 2 to 3 cm proximal to the transverse osteotomy. The distal cable/wire was secured tightly, the middle one not quite as tightly, and the proximal one even more loosely. This distal-middle-proximal sequence is important to avoid osteotomy fracture. The osteotomy site was filled with autologous bone graft obtained from acetabular and femoral canal reaming following fixation, and the range of motion was tested to ensure stability without impingement.

Patients were not given any brace and were allowed to partially weight bear for the first 6 weeks, with about 25% of body weight transferred through the operated hip. After 6 weeks, weight-bearing precautions were relaxed, and patients were allowed to mobilize without crutches or walking sticks, although some continued to use walking aids up to 3 months. Active ranges of movement of the hip and knee were encouraged from the early post-operative period.

The mean Harris hip score increased from 40 pre-operatively to 90 at the final follow-up. Solid bony union was observed on all post-operative radiographs within 6 months. There was no displacement of osteotomised fragments, positions of fixation cables were unchanged, and there was no metallic wire/cable loosening or bone reaction around the wires. Complete ETO union was noted in one case where a plate was used because of iatrogenic fracture of the medial wall (Fig. 2 A–C).

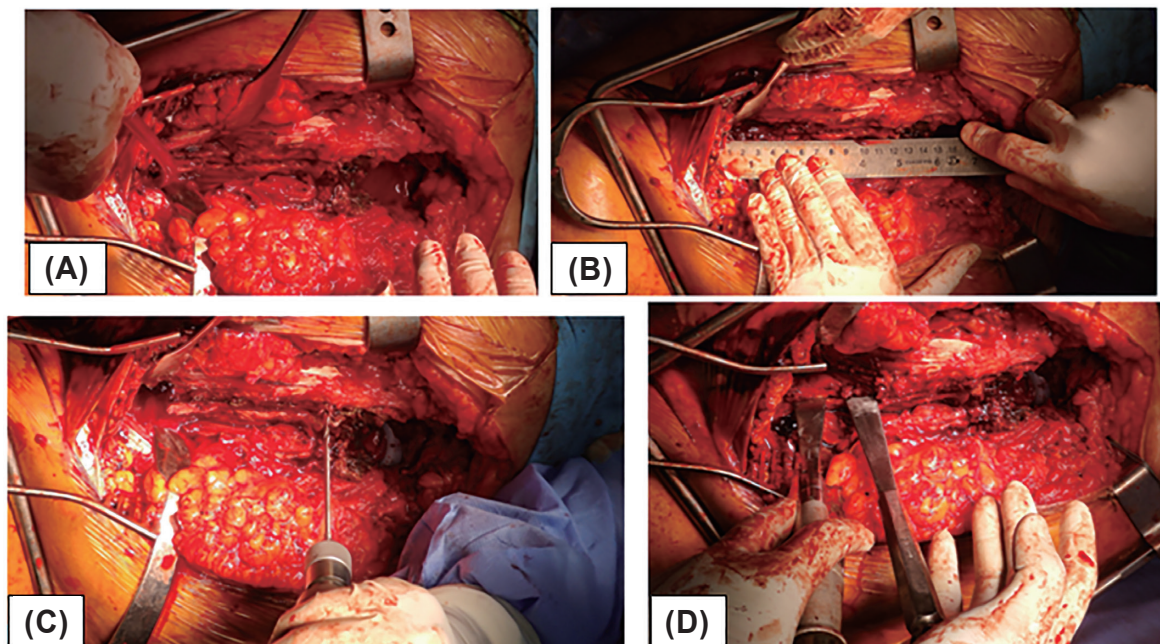


Fig. 1. (A) Exposing the posterior aspect of femur shaft, (B) measuring the osteotomy length, (C) drilling holes along the projected line, (D) opening the bony flap with osteotomes.

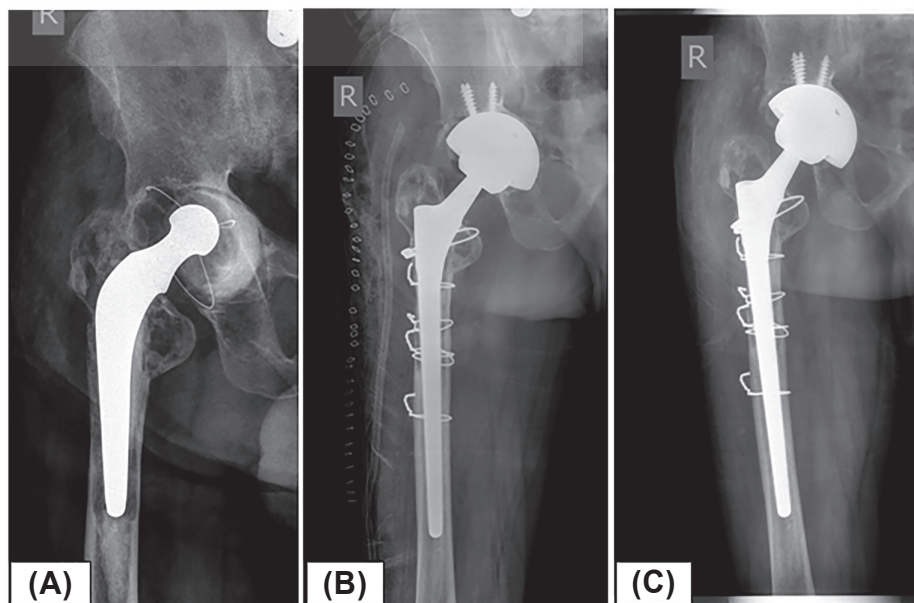


Fig .2. (A) X-ray showing aseptic loosening of the acetabular component and impingement of the femur with the stable cemented femoral component. (B) Immediate post-operative X-ray showing a well-reconstructed extended trochanteric osteotomy (ETO) with cable and metallic wires. (C) Antero posterior X-rays of same patient at the 6-months follow-up showing solid union of the ETO.

There were 5 (3 intra-operative and 2 post-operative) complications related to osteotomy (Table 1). In three cases, the greater trochanter migrated proximally between 5 and 15 mm, but all of these fractures healed spontaneously within 6 months. There were no cases of trochanteric pain, fixation failure, or sciatic nerve palsy.

3. Discussion

ETO is a powerful revision tool for hip arthroplasty surgeons. This safe method enables the removal of mechanically stable cemented or uncemented femoral components. Mechanically stable implants are defined by their failure to move after several firm blows applied to an extraction device secured to the implant. When this occurred, further attempts of forceful manual extraction were abandoned in favour of ETO. Greater trochanter status and bone quality should be carefully assessed. Efforts directed towards access and division of the bone-implant interface cause trochanter fragmentation, perforations, and iatrogenic fractures and increase the risk of non-union. Therefore, ETO that affords a large reattachment surface is preferred to avoid these issues. The level of ETO should be meticulously planned as it varies for different stems. For proximally coated anatomical stems, bone-implant bonding is usually at metaphysis-diaphyseal junction, and the osteotomy length is based on the coated portion of the stem. In cementless fully coated stems and cemented

stems, the osteotomy level should be extended to the tip of the implant. In our series, we performed proximal small osteotomy to the level of coated portion in six patients. In the remaining 25 patients, the ETO was to the implant tip (Table 1).

This approach was first reported by Peters et al.¹ and subsequently by Younger et al.² for removal of well-fixed uncemented stems. The technique was then popularized by Paprosky and colleagues,³ who reported a 92% union rate of ETO with further 7% fibrous union in his series of 166 revision hip replacements. Park et al.⁴ were also great advocates of ETO use. In their series of 62 revision total hip replacements, there was a significantly lower rate of femoral perforations and stem subsidence with ETO. McInnis⁵ observed a high rate of femoral perforations and fractures in the non-ETO group compared to the ETO group. Furthermore, Lerch et al.⁶ advocated the use of an ETO to prevent intra-operative femoral fractures; they reported superior outcomes after ETO compared to cases of intra-operative fracture that require fixation. We encountered two intra-operative iatrogenic fracture of the medial cortex in our series. One was a transverse fracture that was managed with a plate, and the other was an oblique fracture that was managed with cerclage metallic wire. Both cases achieved solid union within 6 months. The rate of stem subsidence was slow; 2 stems subsided 5 to 10 mm within 6 weeks but then stabilized without the need for revision.

Our complication rate was comparable to that reported by Drexler et al.⁷ in a retrospective review of 34 patients, the ETO healed in all cases, and only 2 patients had femoral stem subsidence.

There are few papers on the biomechanical advantages of ETO fixation. Schwab and colleagues⁸ found no significant differences with two versus three cables during biomechanical cadaveric testing. Both cables and wires have been successfully used by many surgeons. Although controversy exists about which is better, cables offer improved tensile strength and resistance to fatigue. In our series, fixation with three metallic wires was adequate in most of the cases; this cost-effective technique achieved good results.

A special situation to consider is managing an infected cemented stem. Even when the implant is loose and extracted, ETO should be considered for extended debridement of the cement to control infection. Late haematogenous infections associated with the in-growth of bone and an extensively porous-coated stem are usually quite sick and not suited for the lengthy procedure. In these cases, ETO should be carried out along the entire length of the prosthesis. In our series, we performed ETO in two infected cemented stems for the purpose of debridement, and revision surgery was done in two stages. In the first stage, the osteotomy site was reconstructed with our standard fixation technique and packed with antibiotic bone cement to control infection. In the second stage after 10 weeks (patients appeared late) because the osteotomy site got united, we had revised with Corail™ (DePuySynthes, Warsaw, IN) stem and we succeeded in controlling the infection in both the cases. Lim et al.⁹ described ETO use as part of the approach in two-stage revision of periprosthetic joint infections. In 23 consecutive cases, ETO was used during the first stage. After osteotomy closure, a cement spacer or temporary stem coated with cement was inserted. The authors reported 100% union of the ETO as confirmed by radiological and clinical assessment after the second-stage procedure. Among 12 femoral stem fractures, there was 1 case where the femoral prosthesis (extensively porous-coated and distally fixated cementless long stem) demonstrated fractures 8 cm from the stem's shoulder. Initially we planned to perform an osteotomy to 1 cm distal to the fractured level, and then use an extraction device to pull the fractured stem. However, we were not able to extract the broken stem because of extensive bone in-growth and on-growth circumferentially. We had to extend the osteotomy (double ETO,) to the implant tip to extract the broken stem. We believe that it is essential to plan an ETO to the tip of the stem, especially for extensively

porous-coated and distally fixed cementless long stems. It is better to avoid a double ETO as it increases the risks of iatrogenic fracture and non-union.

In 1972, Charnley¹⁰ advocated initial bed rest with abduction pillows for 3 weeks, followed by in-hospital mobilization for 1 week before discharge. This regimen was subsequently relaxed, and earlier mobilization became the norm. The current standard rehabilitation protocol consists of a minimum of 6 weeks protected weight bearing; all our patients followed the early mobilization protocol, and the outcomes were good with minimal complications.

ETO can reduce the risk of greater trochanter fracture and can protect weakened proximal bone. While preserving muscular abductor attachment, ETO can also aid in abductor tensioning with trochanteric slide.¹¹ It allows for excellent femur exposure and in turn enhances acetabulum exposure.

The intention of the study was to evaluate the union rate, complications related to osteotomy, and outcomes after revision hip arthroplasty. The strength of this series is that all procedures were performed by a single surgeon from the posterior approach. In our experience, this approach is preferred if the stem is well fixed, as it allows the management of perforations and fractures. Limitations of this study include its retrospective nature, the small number of patients, and the lack of a control group. Furthermore, the length of clinical and radiological follow-up was limited, as many patients were referred from rural hospitals and had difficulty returning for evaluations.

In conclusion, ETO is an important technique for revision hip surgeons. It is cost effective, safe, saves time, provides excellent access to the femoral canal without compromising the bone stock, and aids removal of the implant and cement mantle. When carefully performed and meticulously repaired using wires and supported by autologous bone graft, ETO results in good functional and radiological outcomes with fewer complications. Intra-operative osteotomy fracture should be fixed with plates and cables/wires.

References

1. Peters PC Jr, Head WC, Emerson RH Jr. An extended trochanteric osteotomy for revision total hip replacement. *J Bone Joint Surg Br* 1993;75:158–9. doi:10.1302/0301-620X.75B1.8110207
2. Younger TI, Bradford MS, Magnus RE, Paprosky WG. Extended proximal femoral osteotomy. A new technique for femoral revision arthroplasty. *J Arthroplasty*

- 1995;10:329–38. doi:10.1016/s0883-5403(05)80182-2
3. Aribindi R, Paprosky W, Nourbash P, Kronick J, Barba M. Extended proximal femoral osteotomy. *Instr Course Lect* 1999;48:19–26.
 4. Park YS, Moon YW, Lim SJ. Revision total hip arthroplasty using a fluted and tapered modular distal fixation stem with and without extended trochanteric osteotomy. *J Arthroplasty* 2007;22:993–9. doi:10.1016/j.arth.2007.03.017
 5. McInnis DP, Horne G, Devane PA. Femoral revision with a fluted, tapered, modular stem seventy patients followed for a mean of 3.9 years. *J Arthroplasty* 2006;21:372–80. doi:10.1016/j.arth.2005.08.022
 6. Lerch M, von Lewinski G, Windhagen H, Thorey F. Revision of total hip arthroplasty: clinical outcome of extended trochanteric osteotomy and intraoperative femoral fracture. *Technol Health Care* 2008;16:293–300.
 7. Drexler M, Dwyer T, Chakraverty R, Backstein D, Gross AE, Safir O. The outcome of modified extended trochanteric osteotomy in revision THA for Vancouver B2/B3 periprosthetic fractures of the femur. *J Arthroplasty* 2014;29:1598–604. doi:10.1016/j.arth.2014.03.020
 8. Schwab JH, Camacho J, Kaufman K, Chen Q, Berry DJ, Trousdale RT. Optimal fixation for the extended trochanteric osteotomy: a pilot study comparing 3 cables vs 2 cables. *J Arthroplasty* 2008;23:534–8. doi:10.1016/j.arth.2007.05.028
 9. Lim SJ, Moon YW, Park YS. Is extended trochanteric osteotomy safe for use in 2-stage revision of periprosthetic hip infection? *J Arthroplasty* 2011;26:1067–71. doi:10.1016/j.arth.2011.03.001
 10. Charnley J. The long-term results of low-friction arthroplasty of the hip performed as a primary intervention. *J Bone Joint Surg Br* 1972;54:61–76.
 11. Chen WM, McAuley JP, Engh CA Jr, Hopper RH Jr, Engh CA. Extended slide trochanteric osteotomy for revision total hip arthroplasty. *J Bone Joint Surg Am* 2000;82:1215–9. doi:10.2106/00004623-200009000-00001
 12. Wagner M, Wagner H. The transfemoral approach for revision of total hip replacement. *Orthop Traumatol* 1999;7:260–76. doi:10.1007/BF03180945