



Single-Stage Computer-Assisted Total Knee Arthroplasty for Arthritic Knee with Supracondylar Distal Femoral Fractures

Ashish Singh*, Purushotam Kumar, Sushil Singh, Kartheek Telagareddy and RN Singh

Department of Orthopaedics, Anup Institute for Orthopaedics and Rehabilitation, India

*Corresponding Author: Ashish Singh, Department of Orthopaedics, Anup Institute for Orthopaedics and Rehabilitation, India.

Received: April 14, 2021

Published:

© All rights are reserved by Ashish Singh, et al.

Abstract

Total knee arthroplasty (TKA) can be an alternative to treat supracondylar distal femoral fractures in elderly patients with a pre-existing osteoarthritis. The present case series of 3 patients evaluates a single-stage treatment technique by TKA for the distal femoral fractures and arthritic knee. It was further assisted for increased accuracy by an image-free navigation system. All the three patients were treated by TKA with a less constrained approach using a Stryker Scorpio NRG cruciate-retaining total knee replacement prosthesis after internal fixation of the femoral fracture and guided by Orthomap precision navigation system. The 6-week and 3-month radiographic evaluation revealed proper positioning, prosthesis maintenance, lower extremity alignment and good fracture union. The clinical evaluation using the mean knee society score improved from 46.6 at six weeks to 85.3 at three months with an improved range of motion of the knee joint. A new term, "Pre-prosthetic fracture", can be considered for such fractures around the knee occurring in combination with arthritis and suitably managed with single-stage total knee arthroplasty.

Keywords: Total Knee Arthroplasty; Distal Femoral Fractures; Navigation System; Arthritis; Single-Stage

Abbreviations

TKA: Total Knee Arthroplasty; DFF: Distal Femoral Fractures; AP: Anteroposterior; MCL: Medial Collateral Ligament; PCL: Posterior Cruciate Ligament; KSS: Knee Society Score; BMI: Body Mass Index

Introduction

Historically, distal femoral fractures (DFF) are not always easily manageable in elderly patients due to co-existing osteoarthritis or even intra-articular damage [1]. These distal supracondylar femur fractures usually occur in elderly patients due to low-energy trauma [2]. It is a dilemma for surgeons to opt for a particular treatment strategy with minimal complications and early mobility. The surgical treatment options include internal fixation, external fixation, or intramedullary nailing [1]. Post-surgical complications include poor knee function, vicious union, mispositioning of im-

plants, prolonged confinement to bed and high morbidity and mortality in elderly patients [1].

Total knee arthroplasty (TKA) is rarely advocated for patients with DFF accompanied by arthritic bones. However, they have shown an advantage over open reduction and internal fixation techniques owing to early mobility and weight-bearing [1]. However, the rate of loosening or mechanical failure of the prosthesis may be of concern in such surgical modalities. Further, mispositioning of the prosthesis can be one reason for failure, loosening, or even reduced functional performance [3].

It is reported that a proper alignment after TKA is associated with reduced pain, early mobility, improved functional performance, and thus improved quality of life [3]. Computer-assisted navigation during surgery is a high-tech progression in TKA tech-

niques to increase the accuracy of alignment [4]. This study describes our successful experience with three arthritic patients who underwent single-stage TKA using Orthomap precision navigation and a cruciate-retaining knee prosthesis after anatomical reduction of the fracture and fixation. To the best of our knowledge, this is the first report highlighting the use of computer-assisted navigation in TKA for the treatment of DFF with pre-existing osteoarthritis and using a minimally constrained cruciate retaining prosthesis.

Materials and Methods

We did a retrospective review of 3 cases to analyze the techniques adopted in addition to clinical and radiographic results in patients with knee osteoarthritis who underwent single-stage TKA using computer-assisted navigation and a cruciate-retaining knee prosthesis after open reduction and internal fixation of the fracture. All three patients had presented with displaced DFF and had pre-existing osteoarthritis (Table 1). They were treated with TKA using navigation and simultaneous fixation of the fractures.

Between February 2018 and December 2018, TKA was performed on three patients with pre-existing osteoarthritis at our institute to treat the DFF. All the patients had a knee injury during walking following a fall. Demographic, clinical, and radiological data were documented. They were evaluated clinically and radiologically before the surgery. The osteoarthritis was graded based on the Kallgren-Lawrence grade [5]. All the fractures were classified using the AO Foundation/Orthopedic Trauma Association (AO/OTA) classification [6]. Radiological evaluation was done using anteroposterior (AP) and lateral views and a computed tomography (CT) scan.

Surgical technique

All surgeries were performed under spinal anesthesia in a supine position on a radiolucent operation table. A medial parapatellar skin incision was made and was extended proximally according to the fracture type. The deep medial collateral ligament (MCL) was partially released from the tibial attachments. The displaced fractures were addressed with anatomic reduction, and bone clamps were applied. In order to maintain the fracture reduction during the TKA procedure, temporary Kirshner wire fixation was performed. The anatomical reduction of the fracture was stabilized by locking compression plate and screw in two cases and with 6.5 mm partially threaded cancellous screws with washers in the third case. The navigation pins were fixed, and knee registration was done following it (Figure 2A-AI). The mobility range, valgus-varus

instability, and deformity were assessed. The mechanical axis for all three patients from registering knee anatomy with navigation system was obtained after fixation of the supracondylar fracture. Based on the kinematic mechanical axis and navigation input, distal femoral and proximal tibial cuts were taken while checking the flexion and extension gaps. Further, anterior and posterior condylar cuts and chamfer cuts were taken after confirming the AP and mediolateral dimensions. The trial implant ensued after the tibial sizing (Figure 2A-AI). A thorough assessment was done, including flexion and extension gaps, stability in extension, mid flexion, and full flexion. Once it was found to be perfect, final implantation with cement was done and reverified. The closure was done in layers, and a standard 3 mm suction apparatus was left intra-capsular. A posterior cruciate ligament (PCL) retaining femoral component (Stryker NRG Scorpio, Marwah, USA) was used as an intercondylar box cut for cam, and post mechanism was not required. It may have affected the fracture stability in the case of juxta-articular fractures. The mean tourniquet time was 76 minutes (range: 55 - 95) and the mean blood loss during the operation was 365 mL (range: 220 - 500).

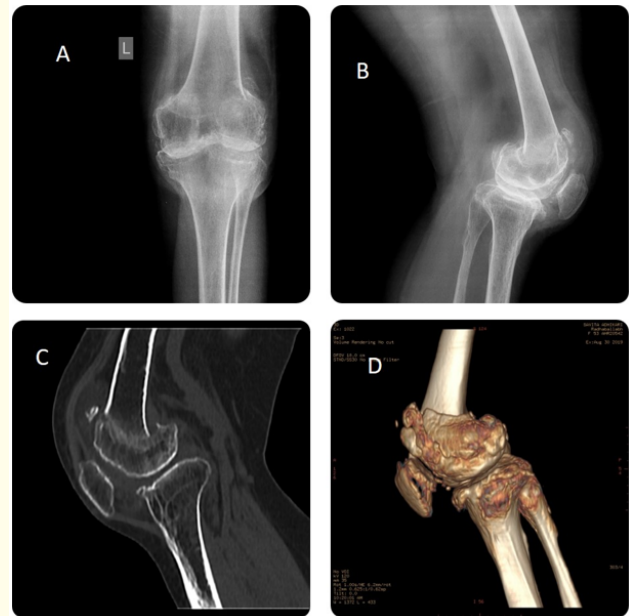


Figure 1: Pre-operative radiological investigations showing distal femur fracture with arthritic knee (a): Anteroposterior (AP) X-ray radiograph Left knee (b) Lateral X-ray radiograph Left knee (c) AP Left knee CT with 3D reformat (d) Lateral Left knee CT with 3D reformat.

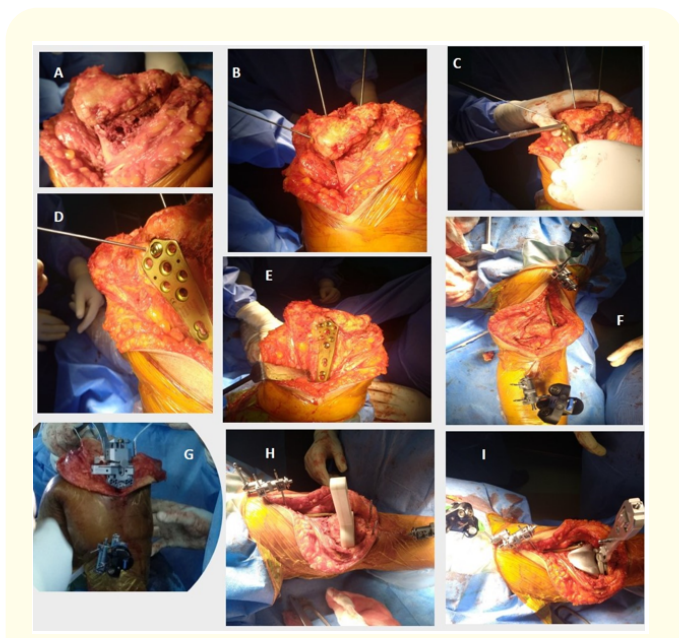


Figure 2: (A) Exposure of fracture: (B) Stabilizing of fractures with multiple Kirshner wires: (C), (D), (E) Fixation with anatomical Locking compression plate, (F) Application of Navigation Pins: (G) Taking Proximal tibial cut using Navigation; (H) Intraoperative picture showing trial implant.

Post-operative care and follow-up

After surgery, a knee brace was applied to be worn for six weeks, depending on the fracture union. On the second post-operative day, the drain was removed, and passive range of motion exercise was performed twice daily. Full weight-bearing was not advocated until further follow up at six weeks. At six weeks, partial weight-bearing using crutches was allowed after reviewing the fracture union.

All patients were evaluated clinically using knee society score (KSS) [7]. Radiographic evaluation was performed at six weeks and three months post-operatively. They were assessed for positioning and maintenance of prosthesis, lower extremity alignment, while the fracture union assessment included cortical or trabecular bridging and fracture line disappearance.

Results

The average patient age was 61 years (range: 53 - 70) and the average body mass index (BMI) was 25.8 with two females and one male patient (Table 1). All the patients had Kallgren-Lawrence grade III-IV osteoarthritis on the injured knee and were treated conservatively. Moreover, none of the patients had a history of previous knee surgery. Two patients had 33B2 complete articular fracture with fragments separated from the shaft, while the third patient had 33B3 (condyle fracture in the coronal plane) according to OTA (Table 1). Surprisingly, all fractures involved the medial condyle. The knee anatomy from the navigation system, both pre, and post-operatively, is mentioned in table 2.

The mean follow-up period was 12 weeks ± 2 weeks. There were no immediate or post-operative complications like infections or deep vein thrombosis. The distal locking screws of the locking compression plate could adequately stabilize the fracture in two cases while it was stabilized with two screws and a washer in the third case. No additional fixation was required since the components were well maintained without the evidence of loosening. The anteroposterior and mediolateral stability of the knees were achieved irrespective of PCL retention.

Patient No.	Age (years) and Sex	BMI	Diagnosis	OTA classification	Navigation used	PCL retention	Implant used	Use of stem
1	70 F	29.9	Grade IV OA with supracondylar fracture	33B2	Yes	No	2x 6.5 mm partially threaded screw with washer	No
2	53 F	21.9	Grade IV OA with supracondylar fracture	33B3	Yes	No	Distal Femur Anatomic Plate	No
3	60 M	25.6	Grade III OA with supracondylar fracture with intercondylar extension	33B2	Yes	No	Distal Femur Anatomic Plate	No

Table 1: Demographic data, fracture classification, osteoarthritis grading, surgical technique used in the patients.

M: Male; F: Female; BMI: Body Mass Index; OTA: Orthopedic Trauma Association, OA: Osteoarthritis; PCL: Posterior Cruciate Ligament.

Patient No.	Pre-operative			Post-operative				
	Flexion Deformity after fixation	Maximum flexion	Mechanical axis/Varus/Valgus	Posterior slope in Tibia	Femoral component flexion	Mechanical axis deviation	Maximum flexion	Mechanical axis/Varus/Valgus
1	5°	131°	173.5° ± 6°	3.5°	4°	1 valgus	139°	175° ± 5°
2	8°	135°	176.5° ± 2.5°	3.5°	3.5°	2 varus	133.5°	178° ± 6.5°
3	20°	137°	171.5° ± 6°	2.5°	0.5°	0.5 valgus	138°	175° ± 1°

Table 2: Navigation data of supracondylar fracture after fixation of fracture and outcome after total knee arthroplasty.

All the fractures united by 12 weeks, and no varus-valgus knee deformity, vicious union, or shortening was observed on the radiographs (Figure 3). The KSS score improved considerably in all three patients. At the 6-week follow-up, the mean KSS score was

46.6 (range: 40 - 50), which improved to 85.3 (range: 85 - 86) at the 12-week follow-up (Table 3). Also, the mean range of motion of the knee joint improved post-operatively (Table 3).

Patient No	Range of motion			KSS score		
	Immediate post-operatively	6-week follow-up	12-week follow-up	Immediate post-operatively	6-week follow-up	12-week follow-up
1	130°	135°	135°	42/100	50/100	86/100
2	120°	130°	130°	30/100	40/100	85/100
3	130°	135°	135°	48/100	50/100	85/100

Table 3: Clinical evaluation of patients post-operatively.

KSS: Knee Society Score.

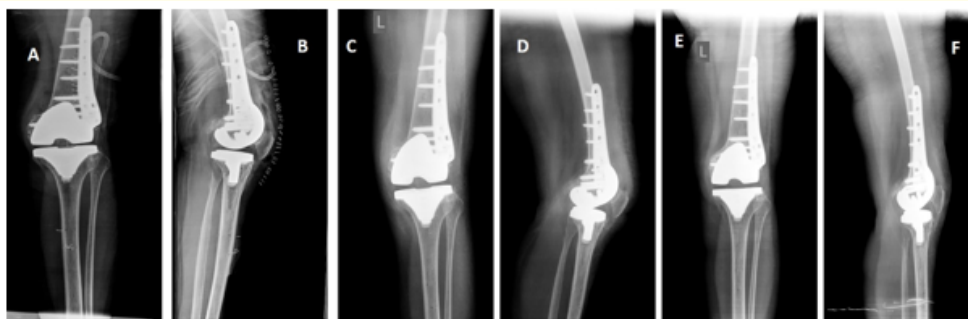

Figure 3: Follow-up radiographs showing good fracture union with no malunion or knee deformity (A) Immediate post-operative anteroposterior radiograph (B) Immediate post-operative lateral radiograph (C) Post-operative anteroposterior radiograph at the end of 6 weeks (D) Post-operative lateral radiograph at the end of 6 weeks, (E) Post-operative anteroposterior radiograph at the end of 3 months (F) Post-operative lateral radiograph at the end of 3 months.

Discussion

A standard TKA after achieving bony union through osteosynthesis in a single step was a better alternative in terms of cost,

time, and pain relief in our elderly patients with osteoarthritis who presented with DFF. Many authors have applied primary TKA to treat DFF in elderly patients with osteoarthritis for their pain

relief and fracture fixation at the same time. Further, since such fractures in the elderly are due to low-energy trauma resulting in stable fractures, they can be treated with standard TKA prosthesis. Different authors have employed different approaches. Yoshino, *et al.* (2001) presented 3 cases of older women suffering from DFF with pre-existing osteoarthritis and treated with posterior stabilized TKA. They concluded that the patient's health status and the fracture type are of importance to consider the option of TKA [8]. Posterior stabilized TKA requires a deep femoral intercondylar box cut for cam and post mechanism, which may reduce the stability of fractures (juxta-articular, supracondylar, or intercondylar). Thus, In, *et al.* (2006) used a cruciate-retaining component for TKA in their three patients for the treatment of DFF (supracondylar or intercondylar) with pre-existing gonarthrosis [9]. Further, Choi, *et al.* (2013) concluded that an appropriate amount of bone stock should be a factor in opting for TKA in arthritic elderly patients to fix DFF. He presented eight such patients who were treated successfully with TKA using Medial Pivot prosthesis and internal fixation [10].

A systematic review analyzed the outcomes of TKA in DFF patients with osteoporotic bones and found mixed results for the application of TKA in such patients. The beneficial outcome may depend on several factors such as the health status of the elderly patients, the type of approach (aggressive or less constrained), and the type of implant. A less constrained knee approach for 33A or 33B fractures while mega prostheses for 33C fractures was advocated based on the systematic review of 13 different studies [1]. Further, studies have shown the use of a hinged prosthesis to be common for treating fractures with osteoarthritis. However, loosening or mechanical failure of such implants have been reported [9,11]. Thus, based on the available literature, we opted for a less constrained approach for TKA with a Stryker Scorpio NRG cruciate-retaining total knee replacement prosthesis after internal fixation of the DFF in a single stage in our patients. This helped in preserving the bone stock in our patients to contemplate for revision surgery in the future. In our patients, all fractures united with a good range of motion, and KSS considerably improved by the end of 12 weeks. Thus, we coined a new term, "Pre-Prosthetic Fracture", for such fractures around the knee occurring in combination with arthritis and suitably managed with a single-stage total knee replacement.

Furthermore, computer-assisted navigation has been documented to be advantageous in TKA due to precise alignment, improved range of motion, and proper placement of implants achieved by accurate incision, ligament balancing, and well-balanced gaps [4,12]. This technique is beneficial in certain complicated cases of

TKA, like obese patients, patients with an abnormal curvature of the femur, patients with extra-articular deformity of femur or tibia, or patients having arthritic knees with severe deformities [4]. Image free navigation is the most common method employed in TKA. However, navigation still is not a guaranteed method and requires a surgeon's skill to be employed in primary TKA with the deformed bony structure like fractures [12]. The success with computer-assisted navigation based TKA depends on the surgeon's compatibility and knowledge of the system. We report here, for the first time, extended use of navigation in TKA with supracondylar femur fracture fixation. It allowed us to deliver good to excellent outcomes with basic non-constrained implants as seen in the radiographs (fracture union) and improvement in KSS.

Some limitations were observed in this retrospective analysis. Firstly, it was on a small number of patients with no control group for comparison. However, DFF in elderly patients is not very common, and thus, these cases are remarkably interesting. Secondly, longer follow-up required for such patients for the determination of true efficacy is not reported. However, a single-stage treatment, bypassing the requirement of two surgeries, may play a role in improved longevity of implants in these patients.

Conclusion

Simultaneous single-stage TKA in patients with osteoarthritis and fracture with or without internal fixation helps better manage the pain with fewer complications, early mobilization and lessens the economic burden rather than two-stage surgery. Also, the use of minimally constrained implants appears to be more bone conserving. Further, we have coined a new term, "Pre-Prosthetic Fracture," to describe such fractures with their subsequent treatment. Also, we found excellent results with the extended use of computer-assisted navigation in treating distal femur fractures and TKA and would propagate image-free navigation in treating such fractures.

Acknowledgements

Special thanks to our chief Orthopaedic orthopaedic surgeon - Dr. R.N. Singh and Anaesthesia and theatre team.

Conflicts of Interest

The authors declare no conflict of interest.

Bibliography

1. Chen F, *et al.* "Primary Total Knee Arthroplasty for Distal Femur Fractures: A Systematic Review of Indications, Implants, Techniques, and Results". *American Journal of Orthopedics* 46.3 (2017): E163-E171.

2. Saurabh A., *et al.* "Total Knee Arthroplasty in a Patient with Open Distal Femoral Fracture with Bicondylar Hoffa Fracture: A Case Report". *Acta Scientific Orthopaedics* 1.3 (2018): 13-16.
3. Cheng T., *et al.* "Does Computer-Assisted Surgery Improve Postoperative Leg Alignment and Implant Positioning Following Total Knee Arthroplasty? A Meta-Analysis of Randomized Controlled Trials?" *Knee Surgery Sports Traumatology Arthroscopy* 20.7 (2012): 1307-1322.
4. Mullaji A and GM Shetty. "Benefits of Computer Navigation in Total Knee Arthroplasty". *Seminars in Arthroplasty: JSES* 23.1 (2012): 18-23.
5. Kohn MD., *et al.* "Classifications in Brief: Kellgren-Lawrence Classification of Osteoarthritis". *Clinical Orthopaedics and Related Research* 474.8 (2016): 1886-1893.
6. Kellam JF., *et al.* "Ao/Ota Fracture and Dislocation Classification Compendium—2018". *Journal of Orthopaedic Trauma* 32 (2018): S33.
7. Scuderi GR., *et al.* "The New Knee Society Knee Scoring System". *Clinical Orthopaedics and Related Research* 470.1 (2012): 3-19.
8. Yoshino N., *et al.* "Primary Total Knee Arthroplasty for Supracondylar/Condylar Femoral Fracture in Osteoarthritic Knees". *The Journal of Arthroplasty* 16.4 (2001): 471-475.
9. In Y., *et al.* "Cruciate-Retaining Stemmed Total Knee Arthroplasty for Supracondylar-Intercondylar Femoral Fractures in Elderly Patients: A Report of Three Cases". *The Journal of Arthroplasty* 21.7 (2006): 1074-1079.
10. Choi NY., *et al.* "Primary Total Knee Arthroplasty for Simple Distal Femoral Fractures in Elderly Patients with Knee Osteoarthritis". *Knee Surgery and Related Research* 25.3 (2013): 141-146.
11. Appleton P., *et al.* "Distal Femoral Fractures Treated by Hinged Total Knee Replacement in Elderly Patients". *The British Editorial Society of Bone and Joint Surgery* 88.8 (2006): 1065-1070.
12. Bae DK and SJ Song. "Computer Assisted Navigation in Knee Arthroplasty". *Clinics in Orthopedic Surgery* 3.4 (2011): 259-267.

Assets from publication with us

- Prompt Acknowledgement after receiving the article
- Thorough Double blinded peer review
- Rapid Publication
- Issue of Publication Certificate
- High visibility of your Published work

Website: www.actascientific.com/

Submit Article: www.actascientific.com/submission.php

Email us: editor@actascientific.com

Contact us: +91 9182824667